



Contents lists available at ScienceDirect

## International Journal of Surgery Case Reports

journal homepage: [www.casereports.com](http://www.casereports.com)

# Correction of secondary deformity after Nuss procedure for pectus excavatum by means of cultured autologous cartilage cell injection



Motoki Tamai<sup>a</sup>, Tomohisa Nagasao<sup>a,\*</sup>, Hiroko Yanaga<sup>b</sup>, Yusuke Hamamoto<sup>a</sup>,  
Tetsukuni Kogure<sup>a</sup>, Yoshio Tanaka<sup>a</sup>

<sup>a</sup> Department of Plastic and Reconstructive Surgery, Faculty of Medicine/Graduate School of Medicine, Kagawa University Kagawa Prefecture, Kida County Miki-Cho Ikenobe 1750-1, Japan

<sup>b</sup> Yanaga Clinic and Tissue Culture Laboratory, 1-2-12 Tenjin, Chuo-ku, Fukuoka 810-0001, Japan

## ARTICLE INFO

## Article history:

Received 4 July 2015

Accepted 15 August 2015

Available online 20 August 2015

## ABSTRACT

**INTRODUCTION:** For some cases of pectus excavatum, ideal chest shape cannot be achieved solely by performing the Nuss procedure. This manuscript presents a case where the residual deformity following Nuss was corrected using injection-transplantation of cultured autologous chondrocytes.

**PRESENTATION OF CASE:** The treatment was performed for an 18-year-old male, who sought improvement of his chest shape after previously undergoing the Nuss procedure. A 1 cm<sup>2</sup> auricular cartilage piece was harvested from his ear. Chondrocytes were isolated from the cartilage piece and were cultured. The cultured chondrocytes were processed into gel form and were injection-transplanted to the deformed region of the patient's chest. The grafted chondrocytes consolidated in one month, presenting elasticity equivalent to ordinary costal cartilage. The patient's chest remains in an optimal shape after a one-year postoperative follow up.

**DISCUSSION:** Secondary correction of the chest deformity after previous operation for pectus excavatum is often tricky, because of the possible adhesion of the lungs or pericardium with the thoracic wall. Transplantation of cultured autologous chondrocytes does not require intra-thoracic maneuvers, and so is less invasive than other surgical interventions. Hence, priority can be placed, in some cases, on the chondrocyte transplantation rather than the re-correction of the thorax with the Nuss procedure or Ravitch procedure.

**CONCLUSION:** Transplantation of cultured autologous chondrocytes is recommended as a useful option for secondary correction of chest deformity after the Nuss procedure.

© 2015 The Authors. Published by Elsevier Ltd. on behalf of Surgical Associates Ltd. This is an open access article under the CC BY-NC-ND license (<http://creativecommons.org/licenses/by-nc-nd/4.0/>).

## 1. Introduction

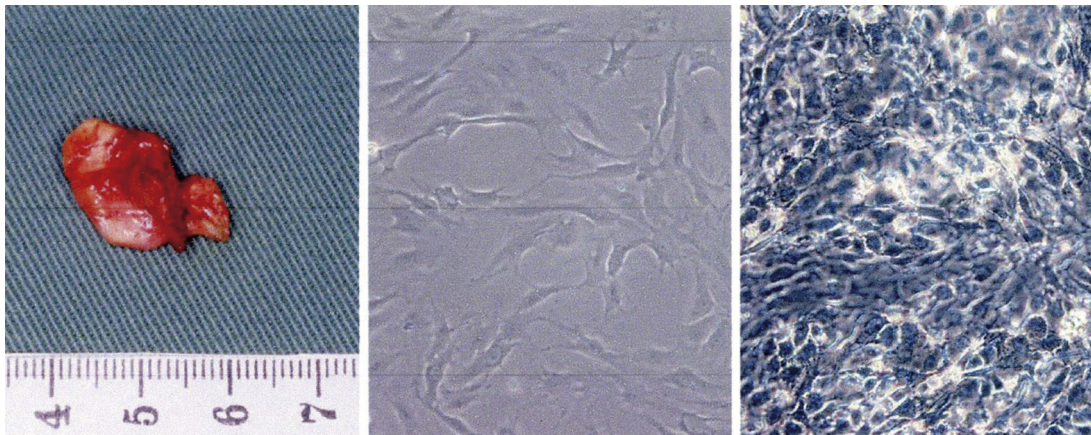
Pectus excavatum is a congenital deformity characterized by concavity of the chest, occurring with frequency of 0.1–0.8 cases per 100 persons [1]. Currently, the Nuss procedure—in which the concave part of the thorax is elevated by using metal bars [2–4] is the standard treatment method for this congenital deformity and is less invasive than conventional methods [5]. However, it does not necessarily produce satisfactory results for all patients. There are cases, where unevenness remains despite the corrective bars or where recurrence gradually develops after their removal. This manuscript introduces a case in which recurrent chest

deformity from pectus excavatum was corrected by transplantation of cell-engineered autologous chondrocytes.

## 2. Cell-engineering technique

Material for cell culture and transplantation was prepared by Yanaga's method as follows [6–9]. A 1 cm<sup>2</sup> auricular cartilage piece was harvested from the patient's auricular choncha (Fig. 1A). The piece was minced and rinsed with phosphate-buffered saline supplemented with penicillin G, streptomycin sulfate, and amphotericin B. The sample was then treated in 0.3% collagenase (Worthington Biochemical, Freehold, N.J.), spun with a stirrer at 37 °C for four hours, and filtered through a 100 μm-pore size cell-strainer (BD Bioscience, San Jose, CA) thereby isolating the chondrocytes. Chondrocytes were seeded at a cell density of 1 × 10<sup>3</sup> cells/cm<sup>2</sup> and cultured in DMEM medium supplemented with 10% autoserum, FGF-2 (5–10 ng/μl, FIBRAST<sup>®</sup>, Kaken Pharmaceuticals, Tokyo), penicillin G (400 unit/μl), streptomycin sulfate (1 mg/μl) and amphotericin B (2.5 μg/μl, Invitrogen Co., UK). The

\* Corresponding author. Department of Plastic and Reconstructive Surgery, Faculty of Medicine/Graduate School of Medicine, Kagawa University Kagawa Prefecture, Kida County Miki-Cho Ikenobe 1750-1, Japan. Fax: +81878912199.  
E-mail address: [nagasao@med.kagawa-u.ac.jp](mailto:nagasao@med.kagawa-u.ac.jp) (T. Nagasao).



**Fig. 1.** (A) Harvested auricular cartilage (B) chondrocytes of the primary passage, immediately isolated from the harvested cartilage (C) chondrocytes present multi-layered structure in multilayer culture system.

chondrocytes in their initial stage of growth are shown in Fig. 1B. The cultured cells were seeded three times on previous lineages [7] During three-passage culture of six weeks, the chondrocytes multiplied by 1000 times and presented a multilayered structure (Fig. 1C). The multilayered chondrocytes were seeded onto the sub-culture cells and gel-formed graft material was obtained as the final product, to be injected into patients.

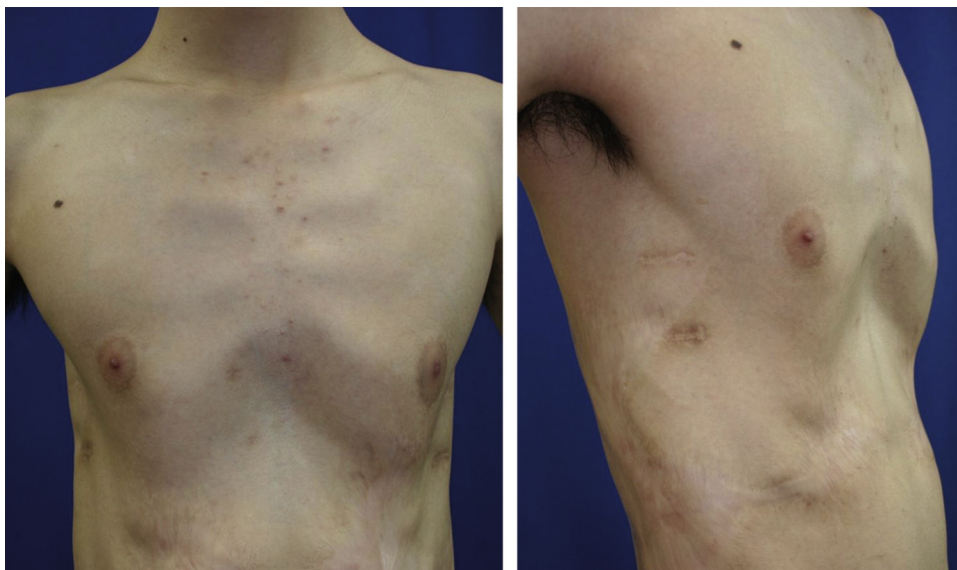### 3. Clinical case

An 18-year-old boy visited the authors' institute seeking improvement of the appearance of his chest. He had previously undergone the Nuss procedure at the age of thirteen and the bar was removed when he was 16. After its removal deformity of the thorax gradually recurred, presenting the appearance shown in Fig. 2 at the age of 18. The options of a second Nuss procedure, reshaping of deformed cartilages with the open approach, cartilage graft from the hypochondrial region of the thorax, and injection-transplantation of cultured autologous chondrocytes were presented to the patient together with detailed explanations of their advantages and disadvantages. The patient requested the transplantation of the cultured autologous chondrocytes. Hence, after obtaining permission of the institutional review board of the authors' institute and informed consent from the patient and his

family, harvesting and processing of the patient's auricular cartilage piece into an injectable cartilage gel were performed according to the previously described method. Thereafter, transplantation of the cultured cartilage was performed under general anesthesia. The skin above the deformed region was marked with dye, and sub-dermal dissection of this region was conducted through a small incision at the midline, at the layer just above the perichondrium of the xiphoid region (Fig. 3). A total of 60  $\mu$ l of gel—with a cell density of 1 to  $5 \times 10^7$  cells per  $\mu$ l—was injected into the dissected pocket made by the dissection, until the injected region became flat. To keep the grafted cartilage in an appropriate position, a sponge was applied to the overlying chest skin and continued for a month. By this time the transplanted cartilage had consolidated and had a firm elastic consistency. One year after the transplantation, the chest shape retains an optimal shape, with no decrease of volume throughout the postoperative observation period (Fig. 4). Computer tomographic imaging taken at six months postoperatively revealed consolidation of the grafted cartilage (Fig. 5).

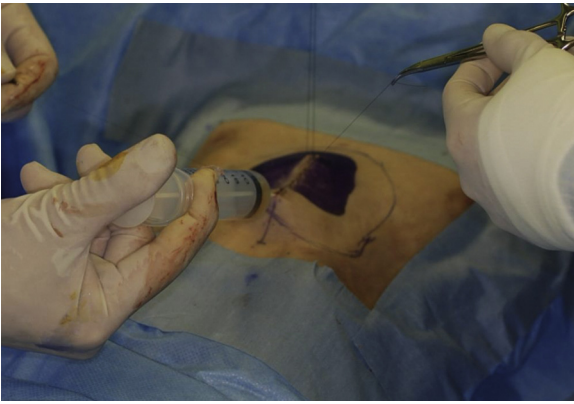
### 4. Discussion

The Nuss procedure for pectus excavatum often fails to achieve full correction particularly of the hypochondrial region since the diaphragm interrupts positioning of correction the bars.



**Fig. 2.** Preoperative condition.



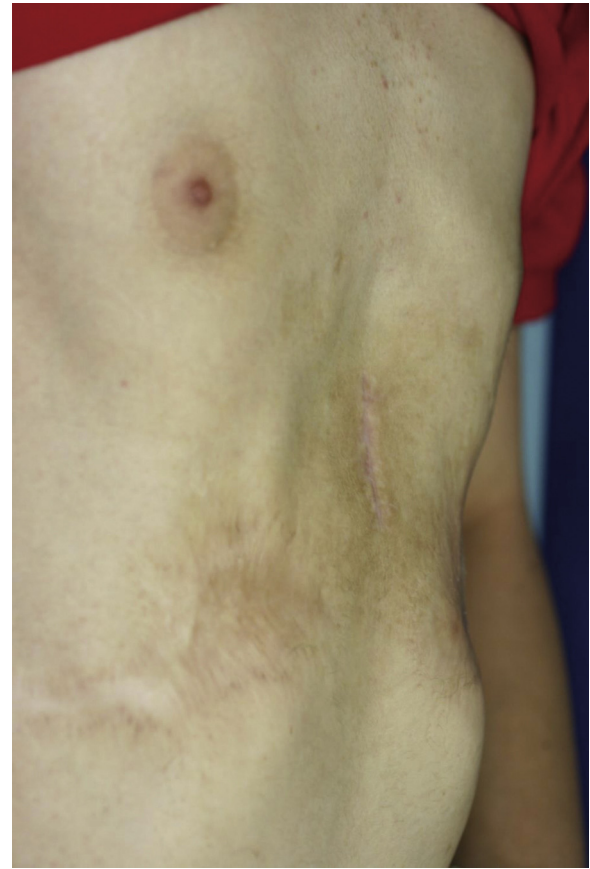

**Fig. 3.** Cultured chondrocytes were injected to the concave region (Blue marking area).

Furthermore some cases develop recurrence of concavity once the correction bars are removed [10]. Treatment options for secondary correction for these deformities include a re-trial of the Nuss procedure, direct reshaping of deformed costal cartilages, and augmentation of the concave region by transplanting cartilage harvested from other regions of the thorax [11]. However, a secondary Nuss procedure is often risky, because of adhesion between the lung or pericardium and the thoracic wall. The latter two methods, reshaping and cartilage transplantation, are invasive and require additional incisions adding to the cosmetic deformity. Hence, we sought an alternative treatment involving cultured autologous auricular cartilage grafting.

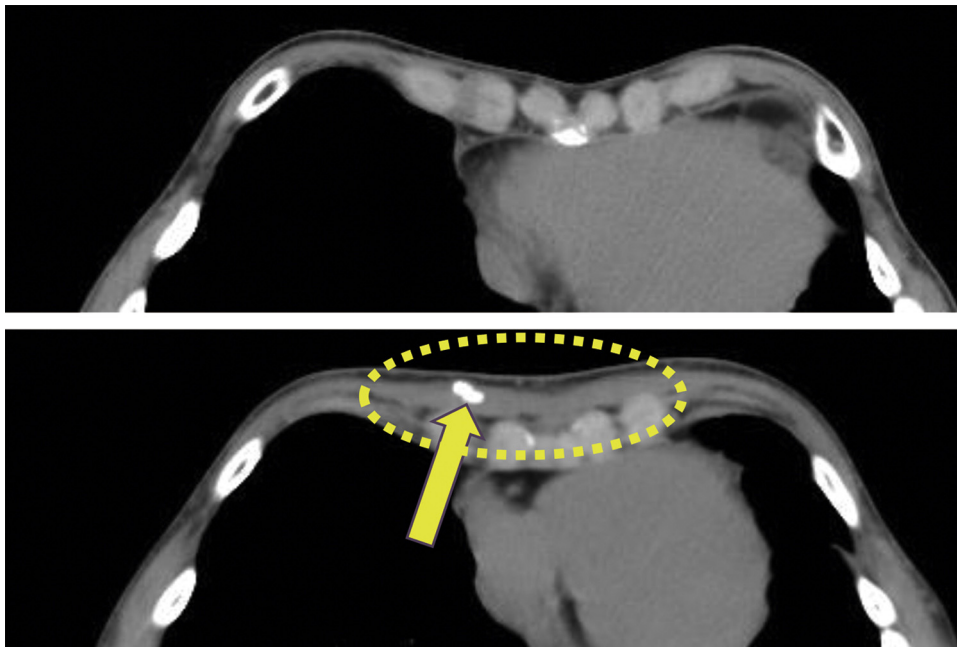
There is no risk of injuring thoracic organs with cultured-chondrocyte grafting, because it can be implemented without intra-thoracic maneuvers. Furthermore, the method can be performed without making long scars on the chest. Instead, it only requires a small one centimeter long post auricular incision to harvest the auricular cartilage.

The disadvantage is that it takes several weeks to prepare the injectable material but this is compensated for by its reduced invasiveness.



**Fig. 4.** Postoperative shape of the thorax at one year after operation.

A further theoretical advantage of our method is that it can also be applied to cases of severe deformity. For such cases cartilage transplantation from other sites on the thorax is not possible, because of insufficient donor cartilage. By contrast with cultured



**Fig. 5.** (Above) Preoperative computed tomographic image. (Below) A computer tomographic image at 5 months after the operation. Injected cartilage cells have consolidate (dotted circle), presenting with partial ossification (arrow).

cartilage, even when the deformity is severe and requires a substantial graft, correction can be achieved by performing several cycles of transplantation. Once harvested, the chondrocytes can be frozen and preserved to be used for several cycles of treatment, if necessary.

Whether or not grafted cartilage remains permanently stable is unknown at the present stage. In our previous experiences augmenting noses, mandibles, and ears with cultured autologous chondrocytes using our technique, neo-cartilage has maintained its original shape with follow-up ranging from one to five years [10,11]. In the present case, the patient's chest retains optimal shape after one-year and we propose further follow-up to evaluate long-term results of the treatment.

Often in the treatment of pectus excavatum, as with other surgical procedures, patients are disappointed when an expected outcome is not achieved with the initial surgery and they are reluctant to agree to another invasive treatment for secondary correction. Grafting cultured autologous neo-cartilage presents a good alternative for such conditions, because of its minor invasiveness. Therefore, we recommend this method as a useful option for correction of secondary deformity after the Nuss procedure.

### Conflict of interest

The authors have no financial interest to declare in relation to the content of this article. No external funding was received.

### Source of funding

The present research was sponsored by Kagawa University hospital which has no involvement with any of following issues.

# Collection, analysis and interpretation of data.

# Writing or organizing the manuscript.

# Decision to submit the manuscript for publication.

### Ethical approval

Ethical approve was obtained by the ethical committee of Kagawa University.

The registry number is Heisei 20-12.

### Consent

The patient's privacy is secured, because the manuscript and its images don't carry any information by which the patient can be identified.

Written informed consent was obtained from the patient for the publication of this case report and accompanying images. A copy of the written consent is available for review by the Editor-in-Chief of this journal on request.

### Author contribution

Motoki Tamai: performance of the treatment.

Tomohisa Nagasao: composition of the manuscript.

Hiroko Yanaga: culture of the chondrocytes.

Yusuke Hamamoto: assistance in surgical procedures.

Tetsukuni Kogure: care-taker of the patient during admission to the hospital.

Yoshio Tanaka: general director and supervisor of the study.

### Guarantor

I, as one of the author of Correction of Secondary Deformaty after Nuss Procedure for Pectus excavatum by means of Cultured Autologous Certilage Cell injection, assure the following issue.

I have read the current "wide for authors" of the international Journal of surgery case report." the manuscript complies with the instruction and condition specified in the "Guide for Author."

I have examined the manuscript; I have agree to its submission with my name in authors' list and take responsibility for the submission.

I assure the material is original. The context of the manuscript has neither been published nor being submitted for publication simultaneously.

If accepted, the manuscript will not be published elsewhere in the same or similar form without written consent from the copyright holder.

### Acknowledgement

We extend our special gratitude to Professor Wayne Morrison (O'Brien Institute in Melbourne) for his kind advice in organizing the present paper.

### References

- [1] R.E. Kelly Jr., M.L. Lawson, C.N. Paidas, R.H. Hruban, Pectus excavatum in a 112-year autopsy series: anatomic findings and the effect on survival, *J. Pediatr. Surg.* 40 (2005) 1275–1278.
- [2] T. Nagasao, M. Noguchi, J. Miyamoto, H. Jiang, W. Ding, Y. Shimizu, K. Kishi, Dynamic effects of the Nuss procedure on the spine in asymmetric pectus excavatum, *J. Thorac. Cardiovasc. Surg.* 140 (2010) 1294–1299.
- [3] T. Nagasao, J. Miyamoto, K. Kokaji, R. Yozu, H. Jiang, H. Jin, T. Tamaki, Double-bar application decreases postoperative pain after the Nuss procedure, *J. Thorac. Cardiovasc. Surg.* 140 (2010) 39–44.
- [4] T. Nagasao, J. Miyamoto, K. Ichihara, H. Jiang, H. Jin, T. Tamaki, Age-related change of postoperative pain location after Nuss procedure for pectus excavatum, *Eur. J. Cardiothorac. Surg.* 38 (2010) 203–208.
- [5] S. Uemura, Y. Nakagawa, A. Yoshida, Y. Choda, Experience in 100 cases with the Nuss procedure using a technique for stabilization of the pectus bar, *Pediatr. Surg. Int.* 19 (2003) 186–189.
- [6] H. Yanaga, K. Imai, K. Yanaga, Generative surgery of cultured autologous auricular chondrocytes for nasal augmentation, *Aesthetic Plast. Surg.* 33 (2009) 795–802.
- [7] H. Yanaga, K. Imai, M. Koga, K. Yanaga, Cell-engineered human elastic chondrocytes regenerate natural scaffold in vitro and neocartilage with neoperichondrium in the human body post-transplantation, *Tissue Eng. Part A* 18 (2012) 2020–2029.
- [8] T. Nagasao, Y. Shimizu, T. Morotomi, N. Takano, H. Jiang, K. Kishi, Irregular location of major pectoral muscle can be a causative factor of pectus excavatum, *Med. Hypotheses* 82 (2014) 512–517.
- [9] B.D. Frari, A.H. Schwabegger, Diced autologous rib cartilage for primary treatment or refinement of minor chest wall deformities, *Plast. Reconstr. Surg.* 128 (2011) 154–162.
- [10] H. Yanaga, K. Imai, Y. Tanaka, K. Yanaga, Two-stage transplantation of cell-engineered autologous auricular chondrocytes to regenerate chondrofat composite tissue: clinical application in regenerative surgery, *Plast. Reconstr. Surg.* 132 (2013) 1467–1477.
- [11] H. Yanaga, K. Imai, T. Fujimoto, K. Yanaga, Generating ears from cultured autologous auricular chondrocytes by using two-stage implantation in treatment of microtia, *Plast. Reconstr. Surg.* 124 (2009) 817–825.

### Open Access

This article is published Open Access at [sciendoirect.com](http://sciendoirect.com). It is distributed under the [IJSCR Supplemental terms and conditions](#), which permits unrestricted non commercial use, distribution, and reproduction in any medium, provided the original authors and source are credited.